

Idiopathic cerebellar ataxia associated with celiac disease: lack of distinctive neurological features

Maria Teresa Pellecchia, Rossana Scala, Alessandro Filla, Giuseppe De Michele, Carolina Ciacci, Paolo Barone

Abstract

Objectives—To determine the occurrence of celiac disease in a population of ataxic patients without definite diagnosis and to characterise distinctive features which may help to differentiate cerebellar ataxia with and without celiac disease.

Methods—Twenty four ataxic patients without definite diagnosis (group A) and 23 ataxic patients with definite diagnosis (group B) were screened for antigliadin (AGAs) and antiendomysium antibodies (EMAs). Patients with a positive AGA or EMA test underwent endoscopic biopsy of the duodenal mucosa.

Results—There was an increased prevalence of celiac disease in group A (3/24) compared with group B (0/23). None of the celiac patients presented gastrointestinal symptoms or malabsorption signs. None of the ataxic patients with celiac disease had early onset ataxia.

Conclusions—Celiac disease is associated with ataxic syndromes without definite diagnosis, suggesting that it plays a part in the pathogenesis of some ataxic syndromes. The absence of distinctive neurological features in ataxic patients with celiac disease suggests that a search should be made for celiac disease markers in all ataxic patients without definite diagnosis. (*J Neurol Neurosurg Psychiatry* 1999;66:32-35)

Keywords: ataxia; celiac disease; antigliadin antibodies; antiendomysium antibodies

Dipartimento di Scienze Neurologiche

M T Pellecchia
R Scala
A Filla
G De Michele
P Barone

Dipartimento di Patologia, Sistemica-Università di Napoli "Federico II", Italy

C Ciacci

Correspondence to:
Dr Paolo Barone, Clinica Neurologica, Ed 17, Department of Neurological Sciences, Via S Pansini 5, 80131 Napoli, Italy.
Telephone-fax 0039 81 7462670;
email: barone@unina.it

Received 10 April 1998 and in revised form 7 July 1998
Accepted 10 August 1998

Celiac disease is a malabsorption syndrome characterised by intolerance to dietary gluten and typical lesions of the small intestine.^{1 2} Neurological complications occur in about 8%-10% of patients with the disease^{3 4} including peripheral neuropathy,^{5 6} progressive multifocal leucoencephalopathy,⁷ cerebellar ataxia,^{4 8 9} progressive myoclonic ataxia,^{10 11} dementia,¹² and myopathy.¹³ These disorders have been generally described as associated with the classic celiac disease featuring weight loss and diarrhoea.^{4 5 14 15}

Gobbi *et al*¹⁶ reported high frequency of celiac disease in patients affected by epilepsy with cerebral calcifications; gastrointestinal symptoms were absent in most of them at the time of duodenal biopsy. Recently, high frequency of gluten sensitivity was found in patients affected by nervous system diseases without definite diagnosis, in the absence of apparent signs and symptoms of classic celiac disease.¹⁷

The aims of the present study were (1) to determine the occurrence of celiac disease in a population of ataxic patients without definite diagnosis and (2) to characterise distinctive features, both clinical and instrumental, which may help to differentiate cerebellar ataxia with and without celiac disease. We screened patients affected by ataxic syndromes without definite diagnosis for antigliadin (AGAs) and antiendomysium antibodies (EMAs), which are markers of celiac disease. We also compared these patients with those affected by ataxia with definite diagnosis, including Friedreich's ataxia and autosomal dominant cerebellar ataxia.

Patients and methods

Forty seven ataxic patients (29 men and 18 women) attending our neurological unit were enrolled in the study and divided into two groups. Group A consisted of 24 patients with ataxic syndromes without definite diagnosis (13 late onset and 11 early onset cerebellar ataxia); group B consisted of 23 patients with definite diagnosis (six autosomal dominant cerebellar ataxia, 17 Friedreich's ataxia). All the patients with autosomal dominant cerebellar ataxia carried a CAG expansion within the SCA2 gene¹⁸; all the patients with Friedreich's ataxia were homozygous for the GAA expansion in the X25 gene.¹⁹ Patients were personally examined by the authors. For each patient pyramidal signs were considered positive when the patient presented Babinski's sign or hyperreflexia plus spasticity; signs of peripheral neuropathy were considered positive when the patient showed absence or reduction of distal reflexes associated with reduced vibratory sense. All patients took part in a semistructured interview investigating any gastrointestinal complaint or malabsorption symptom (diarrhoea, weight loss, flatulence, constipation). Indicators of malabsorption, including haemoglobin, folate, iron, and calcium, were screened in both groups. IgG and IgA AGAs were detected by enzyme linked immunosorbent assay (ELISA; Alfa-Gliatest, Eurospital, Trieste, Italy) in duplicate 5 µl serum samples. The upper limit of the normal range was 20 AU for both IgA and IgG AGAs. The EMAs were measured by indirect immunofluorescence.²⁰

Subjects with a positive AGA or EMA test underwent endoscopic biopsy of the duodenal mucosa. Diagnosis of celiac disease was made in patients with presence of AGAs or EMAs in serum samples and a jejunal biopsy, proving the existence of subtotal or total atrophy of the mucosa according to the criteria of Marsh.²¹

Table 1 Ataxic patients without definite diagnosis (group A)

Patient	Sex	Age (y)	Age of onset (y)	Symptoms at onset	Pyramidal signs	Signs of peripheral neuropathy	NCS	Brain MRI	Gastrointestinal symptoms	Malabsorption signs	AGA/EMA	Duodenal biopsy
1	M	37	12	Aggressiveness, ataxic gait	No	No	P	A	No	No	N	NP
2	M	22	15	Ataxic gait, spasticity	Yes	Yes	N	A+C+WM	Colic pain, constipation	No	N	NP
3	M	38	27	Ataxic gait	No	No	P	A	No	No	AGA and EMA+	P
4	M	43	25	Weakness, dizziness	No	No	NP	A+B+C	Constipation	No	N	NP
5	F	21	16	Ataxic gait	No	No	N	A	No	No	N	NP
6	M	27	6	Ataxic gait	Yes	No	NP	A+B+C	No	No	N	NP
7	F	58	52	Ataxic gait	No	No	NP	A	No	No	N	NP
8	F	37	22	Writing difficulties	No	No	NP	A	No	No	N	NP
9	M	31	15	Ataxic gait	Yes	No	P	A	No	No	N	NP
10	M	58	46	Ataxic gait	No	No	N	A+B+C	No	No	N	NP
11	F	55	50	Ataxic gait	No	No	P	A+B+C	Constipation	No	N	NP
12	M	23	7	Ataxic gait, dysarthria	No	No	NP	A+WM	Constipation	No	N	NP
13	F	59	57	Ataxic gait, dysarthria	No	No	N	A+B	No	No	N	NP
14	F	26	26	Ataxic gait	No	Yes	P	A	No	No	N	NP
15	M	64	49	Ataxic gait, dizziness	No	No	N	A+C	No	No	N	NP
16	M	55	8	Ataxic gait	No	Yes	NP	A	Colic pain, diarrhoea	No	N	NP
17	M	64	62	Ataxic gait	No	No	N	A+C	No	No	IgG AGA+	P
18	M	33	12	Dysarthria, ataxic gait	Yes	No	N	A+C	No	No	N	NP
19	F	34	27	Ataxic gait	No	No	P	A	No	No	IgG AGA+	P
20	M	48	43	Ataxic gait, dysphonia	Yes	No	N	A+C	No	No	N	NP
21	M	41	25	Dysarthria	No	Yes	P	A	Constipation	No	N	NP
22	M	62	39	Ataxic gait	No	Yes	NP	A+B+C	Constipation	No	N	NP
23	M	53	50	Unsteadiness, ataxic gait	No	Yes	P	A	No	No	N	NP
24	M	66	62	Weakness, tremor	No	Yes	P	A	No	No	N	NP

Pyramidal signs=Babinski's sign or hyperreflexia plus spasticity; signs of peripheral neuropathy=absence or reduction of distal reflexes associated with reduced vibratory sense; NCS= nerve conduction studies

P=pathological; N=normal; NP=not performed; A=cerebellar atrophy; B=brainstem atrophy; C=cortical cerebral atrophy; WM=white matter abnormalities
AGA=antigliadin antibodies; EMA=antiendomysium antibodies.

In all patients with pathologically confirmed diagnosis of celiac disease, serum vitamin E and vitamin B₁₂ concentrations, antiPurkinje cell, antigranular cell, antiGolgi cell, and antimolecular layer cell antibodies were detected. All patients gave informed consent.

Results

Tables 1 and 2 show clinical, neurophysiological, and neuroradiological findings of ataxic patients included in group A (without definite diagnosis) and group B (with definite diagnosis) respectively.

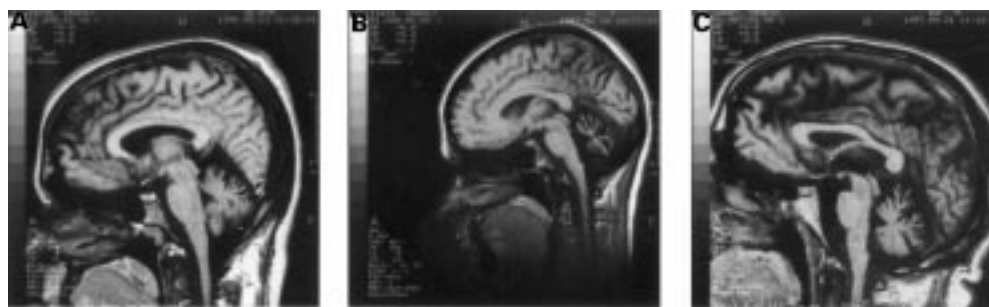
Three out of 24 patients of group A (12.5%) had raised AGAs in their serum samples; two of them had raised IgG AGA alone, in the absence of IgA deficiency; the third patient had raised IgG and IgA AGAs and was EMA positive. Duodenal biopsies disclosed features typical of celiac disease with villous atrophy, elongated crypts, and an inflammatory infiltrate in the lamina propria associated with increased number of intraepithelial lymphocytes in all AGA positive patients. Interestingly, gastrointestinal complaints or malabsorption signs,

Table 2 Ataxic patients with definite diagnosis (group B)

Patient	Sex	Age (y)	Age of onset (y)	Diagnosis	Symptoms at onset	Pyramidal signs	Signs of peripheral neuropathy	NCS	Brain MRI	Gastrointestinal symptoms	Malabsorption signs	AGA/EMA
1	M	60	48	ADCA	Ataxic gait	No	Yes	P	A+B	Alternating constipation and diarrhoea	No	N
2	M	51	50	ADCA	Dysarthria	No	Yes	N	A	No	No	N
3	M	43	34	ADCA	Ataxic gait, dysarthria	No	No	P	A	No	No	N
4	F	44	36	ADCA	ataxic gait, dysarthria	No	No	P	A+C	No	No	N
5	M	59	49	ADCA	Ataxic gait, falls	Yes	No	NP	A+B+C	No	No	N
6	F	28	17	ADCA	Upper limbs tremor	Yes	No	N	A+B+C	Constipation	No	N
7	M	46	33	FA	Ataxic gait	No	Yes	P	A	No	No	N
8	F	27	14	FA	Ataxic gait	Yes	Yes	P	A	Constipation	No	N
9	F	29	12	FA	Ataxic gait	Yes	Yes	P	VE	No	Iron deficiency	N
10	M	35	17	FA	Ataxic gait	Yes	Yes	P	NP	Constipation	No	N
11	M	20	14	FA	Ataxic gait	Yes	Yes	P	N	Dyspepsia	No	N
12	M	43	26	FA	Ataxic gait	No	Yes	P	N	No	No	N
13	M	29	15	FA	Lower limbs weakness	Yes	Yes	NP	NP	No	No	N
14	F	26	14	FA	Ataxic gait	No	Yes	P	A	Constipation	No	N
15	F	29	18	FA	Ataxic gait	Yes	Yes	P	A	No	No	N
16	M	23	18	FA	Lower limbs weakness	No	Yes	P	NP	Constipation	No	N
17	M	24	20	FA	Ataxic gait	No	Yes	P	NP	No	No	N
18	F	17	11	FA	Ataxic gait	No	Yes	P	N	No	No	N
19	F	32	12	FA	Ataxic gait	Yes	Yes	NP	NP	No	No	N
20	F	23	3	FA	Ataxic gait	Yes	Yes	NP	NP	No	No	N
21	F	28	20	FA	Ataxic gait	No	Yes	P	A	No	No	N
22	F	48	30	FA	Lower limbs tremor	Yes	Yes	P	NP	No	No	N
23	M	20	12	FA	Ataxic gait	Yes	Yes	P	NP	No	No	N

ADCA=autosomal dominant cerebellar ataxia; FA=Friedreich's ataxia; pyramidal signs=Babinski's sign or hyperreflexia plus spasticity; signs of peripheral neuropathy=absence or reduction of distal reflexes associated with reduced vibratory sense; NCS: nerve conduction studies

P=pathological; N=normal; NP=not performed; A=cerebellar atrophy; B=brainstem atrophy; C=cortical cerebral atrophy; VE=ventricular enlargement
AGA=antigliadin antibodies; EMA=antiendomysium antibodies.



T1 weighted MRI of celiac patients showing (A, B) cerebellar atrophy in patients 3 and 19, respectively; (C) cerebellar, brainstem, and cortical cerebral atrophy in patient 17.

which are the commonest presentation in patients with celiac disease, were absent in these cases, and were reported in eight out of 21 of the non-celiac patients in group A. Vitamin E and B₁₂ concentrations were in the normal range. Anticerebellar antibodies were absent in the three patients with celiac disease.

No differences were found in the clinical features and symptoms at onset between group A patients with and without celiac disease. However, none of the patients with celiac disease had early onset ataxia, whereas onset was before 20 years in eight out of 21 of the remaining patients of group A. Magnetic resonance imaging of patients with disease showed cerebellar atrophy (patient 3 and patient 19; figure A, B); and cerebellar, brainstem, and cortical cerebral atrophy (patient 17; figure C). Similar neuroimaging abnormalities were found in other ataxic patients without celiac disease.

None of the patients with celiac disease had clinical signs of peripheral neuropathy; however, in two of them we found neurophysiological abnormalities mainly consisting of a decrease of sensory and motor conduction velocities (table 3). Similar neurophysiological abnormalities were found in the other seven ataxic patients of group A.

Patients of group B (control group) showed clinical, neurophysiological, and neuroradiological features consistent with the diagnosis. Gastrointestinal complaints, including constipation, dyspepsia, and alternating constipation and diarrhoea occurred in seven out of 23 patients; one patient had iron deficiency. However, none of the patients in group B was AGA or EMA positive.

Discussion

We found a prevalence of three of 24 patients with celiac disease among ataxic patients without definite diagnosis compared with none of 23 among those with definite diagnosis. The frequency of celiac disease in the first group (12.5%) is at least 20 times higher than that in large scale population studies.^{22, 23} Recently, Hadjivassiliou *et al*¹⁷ reported an increased frequency (16%) of celiac disease in patients established by biopsy with nervous system diseases (especially ataxia and peripheral neuropathy) without definite diagnosis. In this study we confirmed the increased prevalence of celiac disease in a population of ataxic patients without definite diagnosis. Furthermore, Hadjivassiliou *et al*¹⁷ reported in their study that nine out of 25 ataxic patients of their population had a gluten sensitivity (AGA or EMA positivity without histological changes of celiac disease). In our study, however, we found no case of gluten sensitivity in the absence of histological changes of celiac disease.

The present study is the first attempt to correlate clinical and instrumental features of ataxic patients with the presence of celiac disease. We failed to find any clinical difference between ataxic patients with celiac disease and other ataxic patients without definite diagnosis, with the exception that none of the patients with celiac disease presented an early onset ataxia compared with the remaining patients. In addition, MRI and neurophysiological findings did not help to differentiate ataxic patients with and without celiac disease.

Frequent but anecdotal reports have described the association of ataxia and classic celiac disease, in which gastrointestinal symptoms preceded or were concomitant with neurological signs.^{4, 8, 9, 15, 24, 25} Two single cases of cerebellar ataxia associated with unsuspected celiac disease were reported by Hermanzeski *et al*²⁶ and Kristoferitsch *et al*²⁷ respectively. Similarly, in our patients the ataxic syndrome was the main clinical manifestation in the absence

Table 3 Nerve conduction studies in patients 3 and 19 (group A). Conduction studies were performed with needle electrodes according to Behse and Buchthal²

	Patient 3	Patient 19	Normal values
Median nerve:			
Motor conduction			
Distal latency (ms)	3.7	4	3.9*
Distal potential amplitude (mV)	12	21.1	8†
Conduction velocity (m/s):			
Elbow-wrist	60.9	55	54‡
Sensory conduction:			
Potential amplitude (µV)			
At wrist	8.8	10.3	6‡
At elbow	2.5	6.3	2.5‡
Conduction velocity (m/s):			
Digit III-wrist	42.5	49	51‡
Wrist-elbow	64.1	58.2	60‡
Tibial nerve:			
Motor conduction			
Distal latency (ms)	6.7	4.1	4.8*
Distal potential amplitude (mV)	4.85	6.6	6‡
Conduction velocity (m/s)			
Popliteal fossa-internal malleolus	40.2	44.2	52‡
Sensory conduction			
Potential amplitude (µV)			
At internal malleolus	0.5	0.62	0.3‡
At popliteal fossa	0.5	0.33	0.2‡
Conduction velocity (m/s)			
1st toe-internal malleolus	30.7	30.3	38‡
Internal malleolus-popliteal fossa	55.7	52.8	49‡

*Upper limits of the normal range.

†Lower limits of the normal range.

‡Pathological values are italicised.

of any finding suggestive of malabsorption (subclinical celiac disease).

Mauro *et al*⁸ and Battisti *et al*²⁸ described single cases of cerebellar ataxia and vitamin E deficiency in the course of classic celiac disease; cerebellar symptoms improved after vitamin E supplementation, suggesting that selective vitamin E malabsorption was the cause of the neurological manifestations. On the other hand, Ackermann *et al*²⁴ described one patient with classic celiac disease featuring ataxia, tetraparesis, sensory neuropathy, and vitamin E deficiency who did not improve with vitamin E supplementation. Muller *et al*²⁹ reported four patients with neurological complications of celiac disease; three of them presented an ataxic syndrome. Vitamin E concentration was normal in the first patient, just below the lower limit in the second patient, who did not improve after vitamin E supplementation. Vitamin E concentration was not assessed in the third patient. Ward *et al*⁸ and Ghezzi *et al*²⁵ reported single cases of ataxic syndrome and classic celiac disease with normal vitamin E concentrations. In our patients vitamin E concentration was normal, suggesting that vitamin E deficiency is not necessarily responsible for the ataxic syndrome in celiac disease.

Several reports have described the association of classic celiac disease and peripheral neuropathy, including demyelinating sensorimotor neuropathy,²⁹ axonal neuropathy,^{5 14} and mononeuropathy multiplex.⁶ A wide range of neuropathic disorders, including sensorimotor axonal and motor axonal neuropathy, mononeuropathy multiplex, and demyelinating polyneuropathy, has been recently described in eight patients with subclinical celiac disease.³⁰ In our study two of the three celiac patients had a slight sensorimotor neuropathy.

The mechanisms responsible for neurological complications of celiac disease remain uncertain. The first proposed mechanism is the overt or occult malabsorption of nutrients exerting neurotrophic and neuroprotective effects,¹⁴ but dietary gluten restriction and vitamin supplementation rarely improve the neurological deficits.^{5 9} More recently an immunological mechanism is given more credit in the literature: AGAs have been suggested to be directly or indirectly neurotoxic.^{12 17 31} In our patients with celiac disease we excluded known anticerebellar antibodies as having involvement in the pathogenesis of ataxic syndrome, further supporting AGA neurotoxicity. In conclusion, we suggest that celiac disease plays a part in the pathogenesis of some ataxic syndromes, which is not mediated by malabsorption. The lack of distinctive features of ataxia associated with celiac disease suggests that celiac disease markers should be sought for in all patients with an ataxic syndrome of unknown cause.

1 Trier JS. Celiac sprue. *N Engl J Med* 1991;325:1709-18.

- 2 Halsted CH. The many faces of celiac disease. *N Engl J Med* 1996;334:1190-1.
- 3 Cooke WT, Holmes GKT, eds. Neurologic and psychiatric complications. In: *Coeliac disease*. London: Churchill Livingstone, 1984:197-213.
- 4 Finelli PF, McEntee WJ, Ambler M, *et al*. Adult celiac disease presenting as cerebellar syndrome. *Neurology* 1980;30:245-9.
- 5 Kaplan JG, Pack D, Horoupian D, *et al*. Distal axonopathy associated with chronic gluten enteropathy: a treatable disorder. *Neurology* 1988;38:642-5.
- 6 Kelkar P, Ross MA, Murray J. Mononeuropathy multiplex associated with celiac sprue. *Muscle Nerve* 1996;19:234-6.
- 7 Kepes JJ, Chou SM, Price LW. Progressive multifocal leucoencephalopathy with 10-year survival in a patient with nontropical sprue. *Neurology* 1975;25:1006-12.
- 8 Ward ME, Murphy JT, Greenberg GR. Celiac disease presenting with cerebellar degeneration with normal vitamin E status. *Neurology* 1985;35:1199-201.
- 9 Mauro A, Orsi L, Mortara P, *et al*. Cerebellar syndrome in adult celiac disease with vitamin E deficiency. *Acta Neurol Scand* 1991;84:167-70.
- 10 Lu CS, Thompson PD, Quinn NP, *et al*. Ramsay Hunt syndrome and coeliac disease: a new association? *Mov Disord* 1986;1:209-19.
- 11 Bathia KP, Brown P, Gregory R, *et al*. Progressive myoclonic ataxia associated with coeliac disease. The myoclonus is of cortical origin, but the pathology is in the cerebellum. *Brain* 1995;118:1087-93.
- 12 Collin P, Pirttila T, Nurmikko T, *et al*. Celiac disease, brain atrophy, and dementia. *Neurology* 1991;41:372-5.
- 13 Hall WH. Proximal muscle atrophy in adult celiac disease. *Am J Dig Dis* 1968;13:697-704.
- 14 Cooke WT, Smith WT. Neurological disorders associated with adult coeliac disease. *Brain* 1966;89:683-722.
- 15 Tietge UJF, Schmidt HHJ, Manns MP. Neurological complications in celiac disease. *Am J Gastroenterol* 1997;92:540.
- 16 Gobbi G, Bouquet F, Greco L, *et al*. Coeliac disease, epilepsy, and cerebral calcifications. *Lancet* 1992;340:439-43.
- 17 Hadjivassiliou M, Gibson A, Davies-Jones GAB, *et al*. Does cryptic gluten sensitivity play a part in neurological illness? *Lancet* 1996;347:369-71.
- 18 Pulst SM, Nechiporuk A, Nechiporuk T, *et al*. Moderate expansion of a normally biallelic trinucleotide repeat in spinocerebellar ataxia type 2. *Nat Genet* 1996;14:269-76.
- 19 Filla A, De Michele G, Cavalcanti F, *et al*. The relationship between trinucleotide (GAA) repeat length and clinical features in Friedreich ataxia. *Am J Hum Genet* 1996;59:554-60.
- 20 Catassi C, Ratsch M, Fabiani E, *et al*. Coeliac disease in the year 2000: exploring the iceberg. *Lancet* 1994;343:200-3.
- 21 Marsh MN. Gluten, major histocompatibility complex and the small intestine. A molecular and immunologic approach to the spectrum of gluten sensitivity (celiac sprue). *Gastroenterology* 1992;102:330-54.
- 22 Catassi C, Fabiani E, Ratsch IM, *et al*. The celiac iceberg in Italy. A multicentre antigliadin antibodies screening for celiac disease in school-age subjects. *Acta Paediatr* 1996;412(suppl):29-35.
- 23 Johnston SD, Watson RG, McMillan SA, *et al*. Preliminary results from follow-up of a large-scale population survey of antibodies to gliadin, reticulin and endomysium. *Acta Paediatr* 1996;412(suppl):61-4.
- 24 Ackerman Z, Eliashiv S, Reches A, *et al*. Neurological manifestations in celiac disease and vitamin E deficiency. *J Clin Gastroenterol* 1989;11:603-5.
- 25 Ghezzi A, Filippi M, Falini A, *et al*. Cerebral involvement in celiac disease: a serial MRI study in a patient with brainstem and cerebellar symptoms. *Neurology* 1997;49:1447-50.
- 26 Hermaszewski RA, Rigby S, Dalgleish AG. Coeliac disease presenting with cerebellar degeneration. *Postgrad Med J* 1991;67:1023-4.
- 27 Kristoferitsch W, Pointner H. Progressive cerebellar syndrome in adult coeliac disease. *J Neurol* 1987;234:116-18.
- 28 Battisti C, Dotti MT, Formichi P, *et al*. Disappearance of skin lipofuscin storage and marked clinical improvement in adult onset coeliac disease and severe vitamin E deficiency after chronic vitamin E megatherapy. *J Submicrosc Cytol Pathol* 1996;28:339-44.
- 29 Muller AF, Donnelly MT, Smith CM, *et al*. Neurological complications of celiac disease: a rare but continuing problem. *Am J Gastroenterol* 1996;91:1430-5.
- 30 Hadjivassiliou M, Chattopadhyay AK, Davies-Jones GAB, *et al*. Neuromuscular disorder as a presenting feature of coeliac disease. *J Neurol Neurosurg Psychiatry* 1997;63:770-5.
- 31 Chinnery PF, Reading PJ, Milne D, *et al*. CSF antigliadin antibodies and the Ramsay Hunt syndrome. *Neurology* 1997;49:1131-3.
- 32 Behse F, Buchtal F. Normal sensory conduction in nerves of the leg in man. *J Neurol Neurosurg Psychiatry* 1971;34:404-14.