

SHORT REPORT

Cerebellar abnormalities on proton MR spectroscopy in gluten ataxia

I D Wilkinson, M Hadjivassiliou, J M Dickson, L Wallis, R A Grünewald, S C Coley, E Widjaja, P D Griffiths

J Neurol Neurosurg Psychiatry 2005;**76**:1011–1013. doi: 10.1136/jnnp.2004.049809

Gluten sensitivity can manifest with ataxia. The metabolic status of the cerebellum was investigated in 15 patients with gluten ataxia and 10 controls using proton MR spectroscopy. Significant differences were present in mean *N*-acetyl aspartate levels at short echo time and *N*-acetyl aspartate/choline ratios at long echo time between the patient and control groups. These data support the hypothesis that cerebellar neuronal physiology differs between patients with gluten ataxia and healthy controls.

Gluten sensitivity can have a diverse range of clinical manifestations including enteropathy, dermatopathy, and neurological dysfunction. It is thought to result from a heightened immunological responsiveness to ingested gluten in genetically predisposed individuals. In terms of neurological dysfunction, ataxia (gluten ataxia) is the commonest neurological manifestation.¹ It has been suggested that some patients with gluten ataxia have sensory rather than cerebellar ataxia because of the absence of atrophy of the cerebellum on magnetic resonance imaging (MRI) in 40% of patients.²

In vivo proton MR spectroscopy has been applied to study the classification and pathophysiology of various neurological conditions including neoplasms, viral and retroviral infections, ischaemia, demyelination, the epilepsies and some of the dementias.^{3,4} Often thought of as an adjunct to standard MRI in the clinical setting, proton spectroscopy can yield information about neuronal physiology, overall energy state, membrane turnover, and glial cell status. In the present study, we investigated the cerebellar metabolic status of patients with gluten ataxia assessed by proton MR spectroscopy.

PATIENTS AND METHODS

The patient group consisted of 15 patients (six men, nine women; mean age 61 years (range 37–82)) with gluten ataxia (sporadic ataxia with positive antigliadin antibodies) recruited consecutively from the gluten/neurology clinic based at the Royal Hallamshire Hospital, Sheffield. The clinical characteristics of these patients did not differ from those of 68 patients with gluten ataxia described previously.⁵ An age matched control group consisted of 10 healthy volunteers (three men, seven women; mean age 60 years (range 31–75)). The protocol was approved by the South Sheffield Research Ethics Committee, and all subjects provided informed, written consent. All MR data were acquired on a 1.5 T clinical system (Eclipse, Philips Medical Systems, Cleveland, USA) that utilised a standard quadrature radiofrequency transmit/receive head coil.

Two sets of images were acquired with a total imaging time of 18 minutes. A dual echo, fast spin echo technique (TE = 15

and 75 ms; TR = 8040 ms; echo train length = 4 and 4; ave = 1) was used to acquire high resolution, proton density and T2-weighted images in the transverse plane (acquisition matrix = 256 × 256; field of view = 230 mm; 60 contiguous 2.5 mm thick slices). A T1-weighted volume dataset with isotropic 1 mm³ voxel resolution was acquired using a three dimensional, radiofrequency spoiled fast acquisition in the steady state (RF-FAST) technique (TE = 4.4 ms; TR = 15 ms; $\alpha = 25^\circ$). The three dimensional dataset was acquired with secondary phase encoding applied in the anterior–posterior direction, yielding high resolution images in the coronal plane. From the proton density, T2-weighted, and T1-weighted images, a consensus atrophy rating (none = 0; mild = 1; severe = 2) was obtained from two neuroradiologists blinded to the clinical details.

Proton spectra were obtained from a single 15 mm × 15 mm × 20 mm cerebellar voxel (20 mm in the cranio–caudal direction), the placement of which ensured coverage of the dentate nucleus (fig 1E). All spectra were acquired from the right hemisphere and care was taken to minimise the inclusion of cerebrospinal fluid within the prescribed spectroscopic volume for methodological consistency. Two spectra were acquired from each subject:

- (1) one at short echo time/long repeat time (TE = 20 ms/TR = 3000 ms) using a stimulated echo acquisition mode (STEAM) technique with a mixing time of 12 ms
- (2) one at long echo time/intermediate repeat time (TE = 135 ms/TR = 1600 ms) using a point resolved (PRESS) spin echo technique.

Both sequences had acquisition bandwidths of 1.953 kHz. The total spectroscopic examination time was approximately 30 minutes, which included voxel prescription, automated first order shimming, water suppression, and data acquisition.

The system manufacturer's software package was used for post-acquisition spectroscopic processing. Short TE results were calculated as the areas under the myo-inositol (mI at 3.56 ppm), cholines (Cho at 3.2 ppm), creatines (Cr at 3.0 ppm), glutamate/glutamine (Glx at 2–2.4 ppm), and *N*-acetyl aspartate (NAA at 2.02 ppm) resonances relative to that of unsuppressed water. Long TE results are expressed as ratios under the three prominent resonances assigned to Cho (3.2 ppm), Cr (3.0 ppm), and NAA (2.02 ppm) groups. Following tests for normality, group mean metabolite levels and ratios were compared using two tailed independent samples *t* tests.

Abbreviations: Cho, cholines; Cr, creatines; Glx, glutamate/glutamine; mI, myo-inositol; NAA, *N*-acetyl aspartate; ppm, parts per million; PRESS, point resolved spin echo technique; STEAM, stimulated echo acquisition mode; TE, time of echo

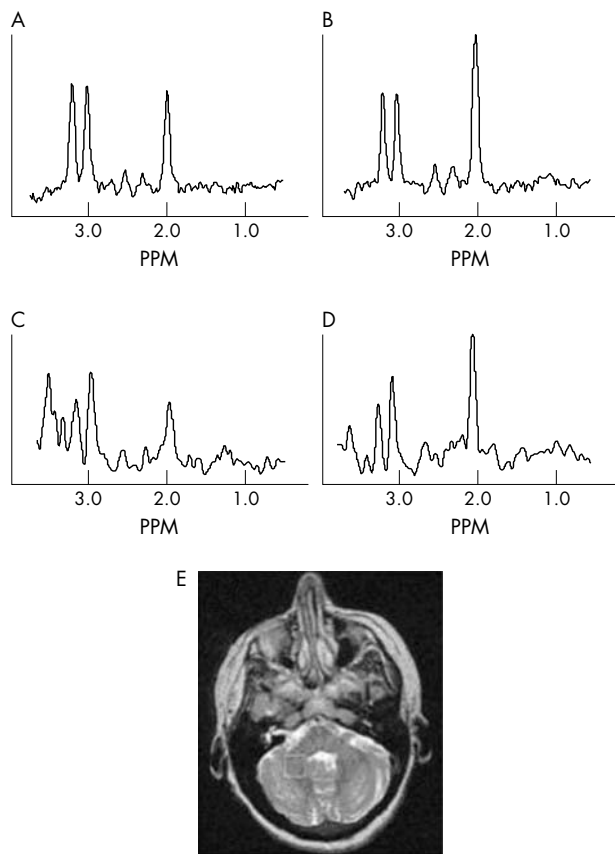


Figure 1 Example long echo time spectra (TE = 135 ms; TR = 1600 ms) from (A) a patient with gluten ataxia and (B) a control subject, and short echo time spectra (TE = 20 ms; TR = 3000 ms) from (C) the same patient and (D) control. (E) Typical placement of the spectroscopic region of interest. Spectral resonances, present at both echo times, correspond to cholines at 3.2 ppm, creatines at 3.0 ppm and *N*-acetyl aspartate at 2.02 ppm. At short echo time (C, D), myo-inositol at 3.56 ppm is also present. PPM, parts per million.

RESULTS

On imaging, 7/15, 5/15, and 3/15 patients scored atrophy ratings of 0, 1, and 2, respectively and 8/10 and 2/10 controls scored ratings of 0 and 1, respectively. The spectroscopic results are summarised in table 1 and example spectra are depicted in fig 1. Analysable spectra were obtained from all patients and controls at long TE and from 14/15 patients and 8/10 controls at short TE. Patient and control groups showed statistically significant differences in NAA/Cho ($p < 0.001$), NAA/Cr ($p < 0.05$) and Cho/Cr ($p < 0.05$) at TE = 135 ms. At TE = 20 ms, the patient and control groups showed a statistically significant group mean difference in NAA only ($p < 0.0005$). Imaging and relative mean NAA areas are combined for patients with gluten ataxia in fig 2. Given the small subgroup subject numbers, no statistical subgroup comparisons are presented, however, the data show no trend in NAA level with increasing atrophy rating.

DISCUSSION

Although in vivo proton MR spectroscopy has been used to investigate many central nervous system diseases, the ataxias have not been the subject of a large number of such investigations. However, some data have been published in this area and have recently been reviewed.⁶ Here, we present the first report detailing spectroscopic findings in patients with gluten ataxia.

Table 1 Mean areas under the spectroscopic metabolite resonances (± 1 SD and relative to unsuppressed water) acquired at TE = 20 ms and metabolite area ratios (± 1 SD) from spectra acquired at TE = 135 ms

	Patients with gluten ataxia	Controls	p value
STEAM: TE = 20 ms			
n (usable spectra)	14	8	
ml	0.62 (0.38)	0.42 (0.08)	0.151
Cho	0.51 (0.22)	0.46 (0.06)	0.491
Cr	0.75 (0.14)	0.69 (0.10)	0.356
Glx	0.37 (0.19)	0.46 (0.12)	0.290
NAA*	0.63 (0.08)	0.79 (0.10)	0.000
PRESS: TE = 135 ms			
n (usable spectra)	15	10	
NAA/Cho*	1.25 (0.22)	1.58 (0.21)	0.001
NAA/Cr*	1.15 (0.18)	1.33 (0.23)	0.042
Cho/Cr*	0.93 (0.12)	0.84 (0.07)	0.040

*Statistically significant differences between the means of the patient and control groups.

ml, myo-inositol; Cho, cholines; Cr, creatines; Glx, glutamate/glutamine; NAA, *N*-acetyl aspartate; PRESS, point resolved spin echo technique; STEAM, stimulated echo acquisition mode.

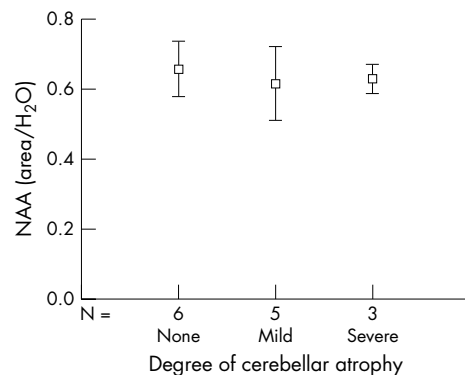


Figure 2 Plot of short echo time *N*-acetyl aspartate (NAA) resonance area (relative to unsuppressed water signal) as a function of atrophy rating (none, mild, severe) for the patients with gluten ataxia. Error bars represent 95% confidence interval from the mean.

The main findings of our preliminary study are the significantly lower NAA, NAA/Cho and NAA/Cr ratios in the gluten ataxia group. Assuming that NAA is largely confined to neuronal cell bodies and axons, this suggests cerebellar neuronal involvement in gluten ataxia. It is thought that reduced neuronal density/death can be inferred from reduction in NAA obtained at short TE and possible reversible neuronal dysfunction can be implicated when NAA signal (and hence NAA/Cho or NAA/Cr ratios) is reduced at long TE.⁷ Assuming equivalent neuronal development, the significantly lower short echo time NAA signal within the gluten ataxia group is suggestive of neuronal loss. It is possible that the results are indicative of cell dysfunction as well as neuronal loss since it has been shown that a strict gluten free diet can lead to improvement of the ataxia in these patients.⁸

No significant changes were observed in Cho or Cr at short TE and a significantly higher Cho/Cr ratio was present in the ataxia group at long TE. As with imaging, spectra acquired at long TE are T2-weighted: the area under a resonance depends upon not only proton density (the dominant factor at short TE) but also the T2 relaxation time of that metabolite. If the chemical environment of a particular metabolite changes (for example, due to a pathological process), this can lead to an alteration in the metabolite's T2, and a change in the signal

returned at long TE. The finding of no change in Cho or Cr at short TE and yet significant change in Cho/Cr at long TE may reflect such a process.⁷

No significant difference was found between the mean mI levels of the patient and control groups. However, a non-significant trend towards higher mI level (approximately 50%) was present in the patient group (as illustrated by the prominent resonance at 3.5 ppm in fig 1C) accompanied by a higher (20%) standard deviation. Further study may add to our knowledge about the pathophysiology involved in gluten related ataxia: it is thought that the mI resonance provides a glial marker and if there is a subgroup of patients who demonstrate a significantly high level of mI, this may suggest a demyelinating process.

The clinical characteristics of gluten ataxia are not distinctive enough to allow clinical recognition from other ataxias.⁵ On published MR data, both imaging and spectroscopy demonstrate atrophy and perturbed spectroscopic metabolites, which can differ between the ataxias.⁶ Small study numbers plus variations in acquisition technique and analysis methodology make direct comparisons difficult, indicating that there is a need for suitable comparative data to ascertain whether proton spectroscopy may provide a useful tool in differentiating between gluten related and other ataxias.

Although the subject numbers are small, the graph of NAA versus atrophy score rating for the patient group suggests that it is not just the ataxia patients with abnormalities on imaging who have low NAA (giving rise to the significant difference between the patient and control groups, see table 1): there appear to be metabolic abnormalities present even in the absence of concomitant parenchymal atrophy (see fig 2). If this is confirmed on further systematic investigation, it will imply that spectroscopy is providing additional information not provided by imaging and may add weight to the hypothesis that gluten ataxia is closely related to cerebellar dysfunction with little or no peripheral sensory contribution.

More importantly, follow up data (currently being collected) will assess whether the observed spectroscopic differences are transitory or permanent, following the introduction of a gluten free diet.⁸ Such evaluation may

establish the role of MR spectroscopy as a tool for monitoring use of new treatments in ataxias.

ACKNOWLEDGEMENTS

The authors wish to acknowledge the spectroscopic skills of the radiographers of the University MRI Unit, Royal Hallamshire Hospital, Dr J Murdoch of Philips Medical Systems for his spectroscopic input, and the sponsorship of Ataxia UK.

Authors' affiliations

I D Wilkinson, J M Dickson, L Wallis, S C Coley, E Widjaja, P D Griffiths, Academic Unit of Radiology, University of Sheffield, Sheffield, England
M Hadjivassiliou, R A Grünewald, Department of Neurology, Royal Hallamshire Hospital, Sheffield Teaching Hospitals NHS Foundation Trust, Sheffield, England

Competing interests: none declared

Correspondence to: Dr I D Wilkinson, Academic Unit of Radiology, C Floor, Royal Hallamshire Hospital, Glossop Road, Sheffield S10 2JF, England; i.d.wilkinson@shef.ac.uk

Received 14 July 2004

Revised version received 22 September 2004

Accepted 29 September 2004

REFERENCES

- 1 **Hadjivassiliou M,** Grünewald RA, Chattopadhyay AK, *et al.* Clinical, radiological, neurophysiological and neuropathological characteristics of gluten ataxia. *Lancet* 1998;**352**:1582–5.
- 2 **Burk K,** Bosch S, Muller CA, *et al.* Sporadic cerebellar ataxia associated with gluten sensitivity. *Brain* 2001;**124**:1013–19.
- 3 **Salibi N,** Brown MA. *Clinical MR spectroscopy, first principles.* Chichester: Wiley-Liss, 1998.
- 4 **Howe FA.** Magnetic resonance spectroscopy in-vivo. In: Markisz JA, Whalen JP, eds. *Principles of MRI.* Stamford CT: Appleton and Lange, 1998.
- 5 **Hadjivassiliou M,** Grünewald RA, Sharrack B, *et al.* Gluten ataxia in perspective: epidemiology, genetic susceptibility and clinical characteristics. *Brain* 2003;**126**:685–91.
- 6 **Viau M,** Boulanger Y. Characterization of ataxias with magnetic resonance imaging and spectroscopy. *Parkinsonism Relat Disord* 2004;**10**:335–51.
- 7 **Wilkinson ID,** Lunn S, Miszkil KA, *et al.* Proton MRS and quantitative MRI assessment of the short term neurological response to antiretroviral therapy in AIDS. *J Neurol Neurosurg Psychiatry* 1997;**63**:477–82.
- 8 **Hadjivassiliou M,** Grünewald RA, Davies-Jones GAB. Gluten ataxia: The effect of gluten free diet. *Ann Neurol* 2002;**52**:S63.